



Review

Canine elbow dysplasia: Aetiopathogenesis and current treatment recommendations

Jacob Michelsen*

School of Animal and Veterinary Science, Charles Sturt University, Locked Bag 588, Wagga Wagga, NSW 2678, Australia

ARTICLE INFO

Article history:

Accepted 10 November 2012

Keywords:

Canine
Elbow dysplasia
Medial coronoid process
Osteoarthritis
Osteochondrosis

ABSTRACT

Elbow dysplasia is a common debilitating condition of large and giant breed dogs. Environmental factors and a complex genetic heritability play a role in predisposing dogs to elbow dysplasia with two aetiopathogeneses suggested for the development of the disease. Osteochondrosis was initially thought to cause elbow dysplasia, but more recent evidence has strongly supported various forms of joint incongruity as the most likely cause in most cases. Radioulnar length discrepancies and humeroulnar curvature mismatch have been implicated as the cause of medial coronoid disease and ununited anconeal process, but radial incisure incongruity and biceps/brachialis muscle forces could possibly play a role in some dogs.

Treatment of elbow dysplasia should address articular pathology, such as fragmented coronoid process, osteochondrosis, cartilage damage and ununited anconeal process as well as any identified underlying causes. Finally, several palliative procedures have been developed to address more advanced elbow disease and might offer improved outcomes compared to conventional medical management.

© 2012 Elsevier Ltd. All rights reserved.

Introduction

Heritable canine elbow dysplasia was defined by the International Elbow Working Group (IEWG)¹ in 1993 to include fragmented medial coronoid process, osteochondrosis of the humerus, ununited anconeal process, articular cartilage injury and incongruity of the elbow joint. Elbow dysplasia is common and has a reported prevalence of 17% in UK Labradors (Morgan et al., 1999, 2000) and 70% in Bernese mountain dogs in The Netherlands (Hazewinkel et al., 1995). It is typically seen in young large and giant breed dogs, but is reported in smaller chondrodystrophic breeds like the Dachshund and French bulldog (Narojek et al., 2008; Sjostrom, 1998). Males are affected at about twice the rate of females (Meyer-Lindberg et al., 2006).

Most cases first present at 6–12 months of age because of persistent forelimb lameness, but some dogs present later in life (>6 years old), with clinical manifestations of medial coronoid disease and little or no prior history of lameness. A further group presents with lameness due to continuing or progressing joint pathology (Fitzpatrick et al., 2009a; Vermote et al., 2010).

Aetiopathogenesis

Genetics

Several large epidemiological studies have examined the genetic basis of elbow dysplasia, which appears to be inherited differently in different breeds. To complicate matters further, there is evidence that the different manifestations of elbow dysplasia could be inherited independently (Clements, 2006; Grandalen and Lingaas, 1991; Hazewinkel, 2006; Lewis et al., 2011; Ma et al., 2004). The differences in inheritance suggest that the syndrome that is currently designated as elbow dysplasia is a common end point for a variety of genetic disorders which disturb elbow development through various mechanisms. Because of the complexity of inheritance and the effects of environmental variables in disease expression, it is unlikely that genetic testing for elbow dysplasia will be possible in the foreseeable future.

Three mechanisms have been suggested for the development of elbow dysplasia including osteochondrosis (OC) (Nap, 1995; Olsson, 1983), various joint incongruities (Gemmill et al., 2005; Kramer et al., 2006), and a biomechanical force mismatch across the elbow joint (Hulse, 2008). All are hypothesised to occur as a result of a genetic predisposition with secondary environmental influencing factors, such as high energy diets, leading to rapid growth rates or excessive exercise (Nap, 1995). Recent evidence

* Tel.: +61 2 6933 2043.

E-mail address: jmichelsen@csu.edu.au¹ See: <http://www.vet-iewg.org> (Accessed 1 April 2012).

has supported various forms of joint incongruity as the most likely mechanism, but OC still appears to play a role in some dogs. The biomechanical force mismatch hypothesis is under development but the evidence to support it is currently weak.

Joint incongruity

There are three joints in the elbow, the humeroradial, humeroulnar and radioulnar (Fig. 1). Three types of joint incongruity have been proposed or demonstrated, namely, (1) radioulnar length mismatch; (2) humeroulnar incongruity, and (3) radioulnar incisure incongruity (Burton et al., 2008). The diagnosis of elbow incongruity by conventional radiology is relatively imprecise, with one small prospective cadaveric study demonstrating that a step of 1.5–4 mm is required to achieve an 86% specificity and 90% sensitivity for detection (Mason et al., 2002). The insensitivity of radiographic diagnosis, coupled with differences between study populations and the lack of standardised imaging protocols, has led to reported incidences of joint incongruity from 14% to 100% in dogs with fragmented coronoid process (Meyer-Lindberg et al., 2006; House et al., 2009; Moores et al., 2008; Samoy et al., 2006). The increasing use of arthroscopy and computerised tomography (CT) imaging over the last decade has refined the understanding of joint incongruity.

Radioulnar length mismatch

Radioulnar length mismatch, with the radius terminating either proximal to or distal to the level of the coronoid processes of the ulna, has been reported in numerous studies (Böttcher, 2011b; Gemmill et al., 2005; Morgan et al., 2000). It has been hypothesised that a short radius transfers weight in excess of normal physiological loads to the medial coronoid process of the ulna (Preston et al., 2000). Excessive cyclic loading leads to fatigue microdamage of the subchondral bone (Olsson, 1993; Wind, 1986a). A level 2 evidence based medicine (EBM) study (Table 2) examined the excised medial coronoid processes of 38 dogs with fragmented medial coronoid process (FCP) and described histological findings of fatigue microdamage and osteocyte loss consistent with this hypothesis (Danielson et al., 2006).

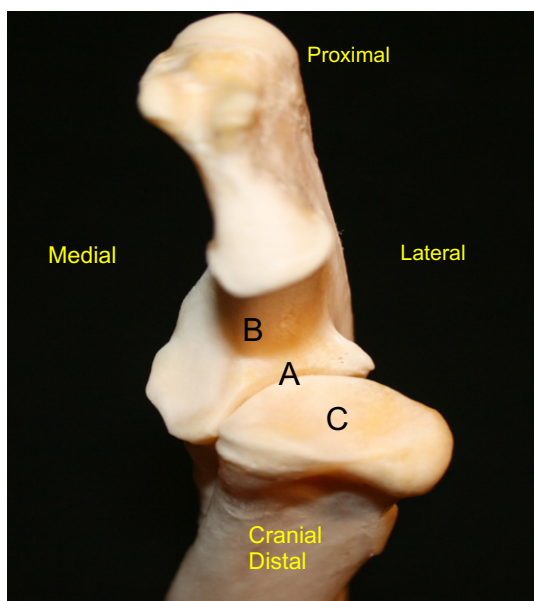


Fig. 1. Craniodistal view of the ulna and humeral head. A, radioulnar joint; B, humeroulnar joint; C, radiohumeral joint.

Numerous studies have also identified an association between FCP and a short radius (Böttcher, 2011b; Kramer et al., 2006; Meyer-Lindberg et al., 2006). The presence of FCP without significant incongruity has been explained by the observation that incongruity is not static, but will increase and decrease at different stages of skeletal growth, often leading to a congruent joint at maturity (Böttcher, 2011b; Trostel et al., 2003). However, the evidence for this hypothesis is anecdotal and studies describing the sequential development of the elbow joint in a number of dogs are necessary for confirmation.

In contrast to a short radius, a short ulna displaces the humeral head proximally relative to the ulna and places excessive loads on the anconeal process. This interferes with bony union of the anconeal process by 20–22 weeks of age in large dogs where there is a separate ossification centre, leading to ununited anconeal process (UAP; Sjöström et al., 1995; Van Sickle, 1966). Once again, this hypothesis is poorly supported by evidence and requires confirmation.

Humeroulnar incongruity

Humeroulnar incongruity is proposed to occur either when the radius of curvature of the ulna notch is less than the curvature of the humeral trochlea, or when a relatively long radius displaces the humeral head cranially from the ulna notch, causing subluxation of the joint (Morgan et al., 2000; Proks et al., 2011). The most frequent cause of humeroulnar incongruity is radial displacement of the humerus, as several studies have found a relationship between joint subluxation and clinical elbow dysplasia, but no relationship to the shape of the ulna notch has been reported, despite breed differences (Collins et al., 2001; Kirberger and Fourie, 1998; Proks et al., 2011). Humeroulnar incongruity is most commonly defined as a form of radioulnar incongruity, where the radius displaces the humerus from the ulnar notch, but further research is required to definitively describe the cause of humeroulnar incongruence, as the current evidence is primarily level 3b to 5.

Radioulnar incisure incongruity and biceps/brachialis mismatch

Radioulnar incisure incongruity and biceps/brachialis muscle mismatch have been proposed to account for the presence of clinical elbow disease limited to the incisure alone. Two potential mechanisms are hypothesised, namely (1) a radioulnar conflict at the incisure leading to crushing of the coronoid process against the radius, and/or (2) compression of the medial coronoid process against the radius by the eccentric pull of the biceps/brachialis muscle group, particularly in flexion (Fitzpatrick, 2006, 2009; Fitzpatrick and Yeadon, 2009; Hulse, 2008; Palmer, 2011; Fig. 2).

Incisure incongruity was suggested to occur through one of several ill-defined mechanisms, such as ligament laxity, a poor fit between the radius and ulna leading to localised force concentration, or compression of the lateral aspect of the medial coronoid process during weight bearing (Fitzpatrick and Yeadon, 2009; Fig. 3). The evidence for these incongruities is limited to three reports, describing clinical disease consistent with the theory and to a biomechanical analysis of the muscle forces of the racing Greyhound (Fitzpatrick et al., 2009a; Samoy et al., 2012; Van Ryssen and Van Bree, 1998). The proposed mechanisms are speculative, which from an EBM perspective is considered level 5. Significant biomechanical testing will be required before the theory can be confirmed or clinically applied.

Osteochondrosis

Osteochondrosis results from a failure of endochondral ossification (Bennett et al., 1981) and as it is a developmental pathology

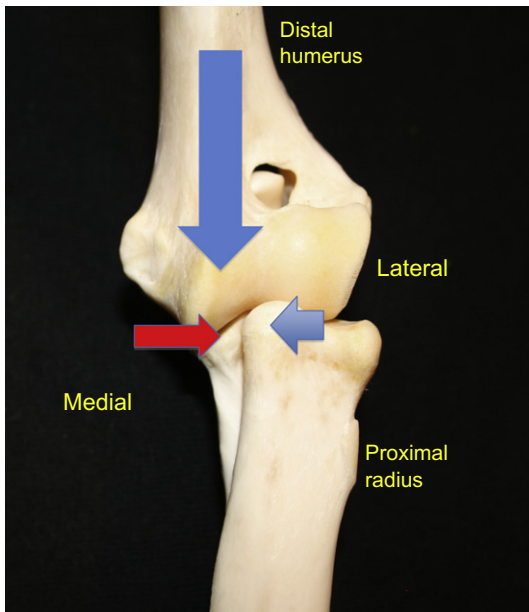


Fig. 2. Cranial view of the extended elbow. Lateral shear force created by longitudinal force acting through the sloped humeral/ulnar interface.

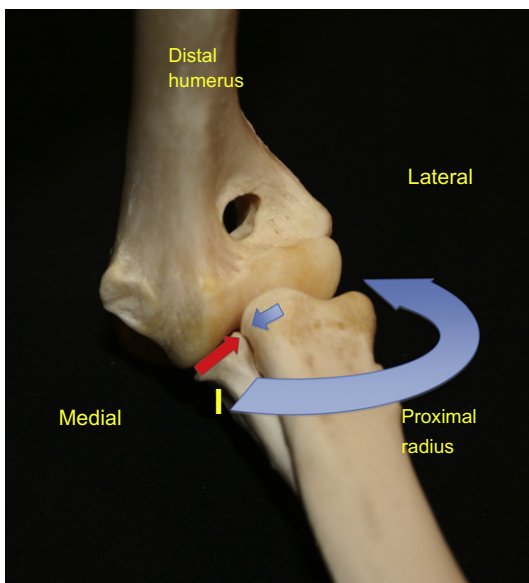


Fig. 3. Cranial view of the flexed elbow. Torsional force created by the abaxial insertion of the biceps/brachialis muscle group compressing the medial coronoid against the radius. I, insertion point of the biceps on the ulna.

which can be present without inflammation, osteochondrosis would seem to be the most appropriate name for the condition until a cartilage flap forms. It was proposed to cause elbow dysplasia through the formation of lesions on the medial humeral condyle, the medial coronoid process or the growth plate of the anconeal process (Bennett et al., 1981; Olsson, 1983; Wolschrijn et al., 2005). The aetiopathogenesis of osteochondrosis is poorly understood, but the failure of chondral and subchondral blood supply is now widely accepted as a crucial factor (Yttrhus et al., 2007).

Osteochondrosis of the medial humeral condyle plays a role in the development of cartilage injury in elbow dysplasia in some dogs (Eckman and Carlson, 1998; Kirberger and Fourie, 1998; Padgett et al., 2005), but the reported prevalence is relatively low (3/100 dogs with elbow dysplasia; Van Ryssen and Van Bree,

1998). Cartilage loss within the joint is more often due to conflict between the contacting joint surfaces, leading to local damage, resulting in a 'kissing lesion' (Kirberger and Fourie, 1998; Trostel et al., 2003).

Pathology resulting from OC or joint incongruity

There are four well-described clinical presentations of elbow dysplasia which cause lameness: (1) medial coronoid disease; (2) OC lesions; (3) UAP, and (4) chronic osteoarthritis (Fitzpatrick and Yeadon, 2009; Hazewinkel, 2006; Samoy et al., 2012; Trostel et al., 2003).

Medial compartment disease is a more recent designation, covering a group of related problems afflicting the medial elbow compartment, including medial coronoid sclerosis, coronoid microfracture, coronoid fragmentation or fissuring, and cartilage damage to the trochlea or coronoid process, with or without joint incongruity (Fitzpatrick and Yeadon, 2009). The term fragmented medial coronoid process has fallen from favour as CT and arthroscopy have revealed that coronoid fragmentation is only part of the pathology present.

The term 'medial compartment disease' is a descriptive term, and can result from several underlying processes. It is by far the most common manifestation of elbow dysplasia, accounting for 85% of the cases of elbow arthroses in one report (Grondalen and Grondalen, 1981). Cartilage injury varies from mild chondromalacia to complete loss, with eburnation of subchondral bone, with or without FCP (Burton et al., 2010; Samoy et al., 2012). Correlations have been found between the degree of incongruity and presence of a medial coronoid fragment, and the degree of cartilage injury present in the joint (Samoy et al., 2012).

It is hypothesised that the articular cartilage injury is secondary to abnormal forces applied by the presence of a step within the joint, or secondary to chronic inflammation created by an avascular fragment of bone (Danielson et al., 2006; Samoy et al., 2012). However, cartilage lesions are sometimes found in the absence of a step, or a FCP, in which case it has been hypothesised to be caused by a resolved joint incongruity present during development, or abnormal loading, perhaps due to radioulnar incisure or bicipital/brachial muscle incongruence (Böttcher, 2011b; Hulse et al., 2010). Evidence for these hypotheses is lacking, being limited to theoretical explanations for observed pathology. As such, it is level 5 evidence and should be evaluated with care.

Ultimately chronic osteoarthritis could result from long standing joint inflammation secondary to cartilage loss, incongruity or subchondral bone injury.

Treatment

The treatment of elbow dysplasia should ideally correct underlying causes before significant joint damage has occurred. Unfortunately, the complex aetiopathogenesis makes the identification of the early stages of disease difficult. Late diagnosis has led to inconsistent clinical outcomes as joint pathology progresses. As a result, numerous procedures to manage end-stage disease have been developed. These include the sliding humeral osteotomy, proximal abducting ulna osteotomy, joint resurfacing, joint replacement, joint denervation and arthrodesis. A decision-making algorithm is shown in Fig. 4.

Radioulnar joint incongruity

The diagnosis of joint incongruity by CT has a reported specificity and sensitivity of about 90% in detecting incongruities of 1 mm or more (Böttcher et al., 2009), which is similar to arthroscopy and

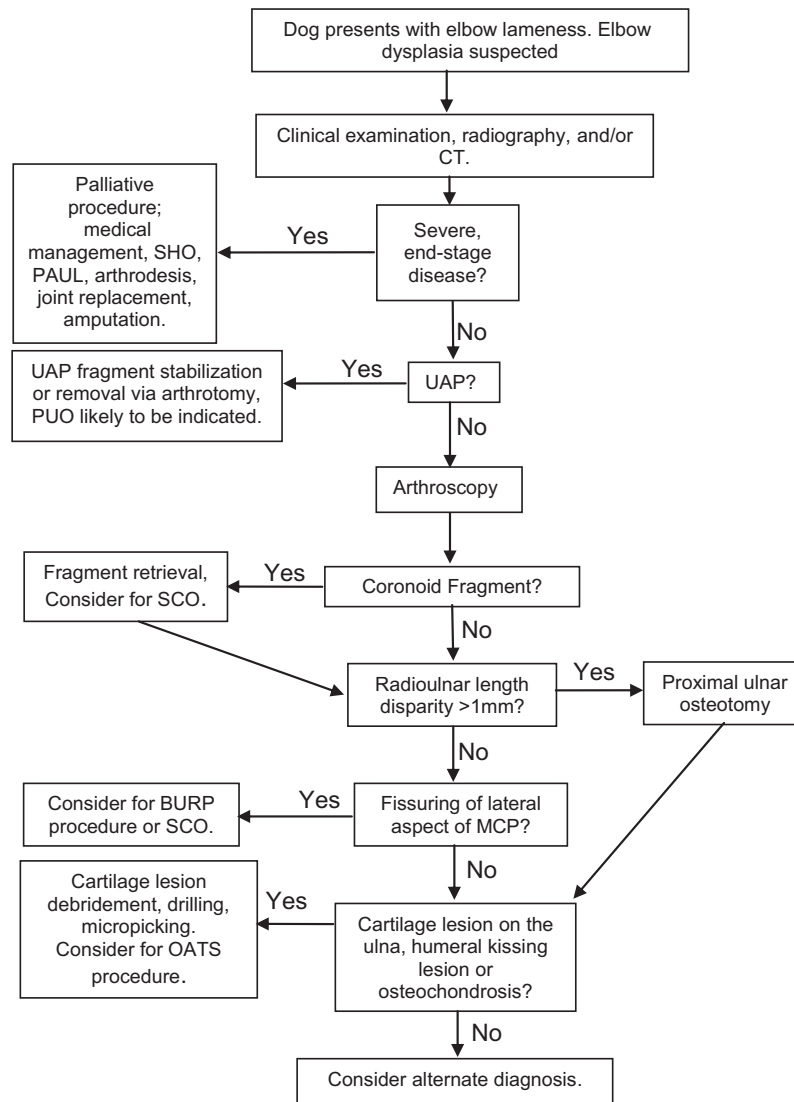


Fig. 4. Algorithm for the treatment of elbow dysplasia. MCP, medial coronoid process; OATS, osteoarticular transfer system; PAUL, proximal abducting ulnar osteotomy; SCO, subtotal coronoidectomy; SHO, sliding humeral osteotomy; UAP, ununited anconeal process.

substantially better than plain radiology, where a step of 2 mm is required to reach 90% specificity and 100% sensitivity (Blond et al., 2005; Tromblee et al., 2007).

Proximal ulna osteotomy (PUO) above the level of the interosseous ligament has been used to correct joint incongruity in the presence of both a short ulna and a short radius, allowing joint congruity to be re-established by permitting movement of the proximal ulnar segment distally or proximally (Preston et al., 2001; Sjostrom, 1998). The osteotomy should be performed from proximolateral to distomedial and caudoproximal to craniodistal to prevent excessive tipping and varus angulation of the proximal ulna segment (Burton and Owen, 2008; Preston et al., 2001). Alternatively, a small intramedullary pin can be used to maintain alignment (Fox, 2012).

While there is evidence to support PUO being effective in addressing radioulnar incongruence, a lack of published studies has resulted in a dearth of information on its long-term benefits. Additionally, PUO carries significant morbidity (Fitzpatrick and Yeadon, 2009), so can only be recommended to treat ongoing lameness. Some joint incongruity has been found to be normal, or at least asymptomatic, in some dogs (Kramer et al., 2006; Wind, 1986b), leading to debate regarding the level of incongruity that

should be tolerated, but the correction of a 1 mm step can be justified based on a finding of incongruence of 1.4 ± 0.9 mm in diseased elbow joints (Kramer et al., 2006).

Joint incongruity as a result of biceps/brachialis contraction

The biceps/brachial ulna releasing procedure (BURP) has been performed to neutralise the compressive force created by the rotational pull of these two muscles (Palmer, 2011). The theorised result is protection of the medial coronoid process from crushing against the radial head (Fitzpatrick, 2009; Fitzpatrick and Yeadon, 2009; Palmer, 2011; Williams et al., 2008). The procedure has been recommended when cartilage injury is minimal and there is fissure formation and/or subchondral sclerosis limited to the area of the radial incisure, identified using radiographs or CT. Additionally, candidates should be young dogs with minimal radioulnar incongruity and mild to marked clinical signs without fragmentation of the medial coronoid (Fitzpatrick and Yeadon, 2009; Palmer, 2011). As there are no controlled studies evaluating the procedure and weak (level 5) evidence for the proposed underlying pathology, it cannot currently be recommended.

Osteochondrosis

Osteochondrosis (OC) can be treated in two ways: (1) the removal of the defective cartilage to the level of the subchondral bone, or (2) the replacement with a core of subchondral bone covered by articular cartilage (Fitzpatrick and Yeadon, 2009; Fitzpatrick et al., 2009c). Traditionally, debridement of the defective cartilage was performed with a curette, ensuring square edges were created with the surrounding healthy cartilage, after which the subchondral bone was drilled or micropicked to encourage fibrocartilage ingrowth (Breur and Lambrechts, 2012). The procedure can be performed via arthrotomy or arthroscopy and generally results in short-term improvement, but also long-term progressive osteoarthritis (Bouck et al., 1995). Evidence for this traditional treatment is based on a number of EBM level 2 and 3 studies in the veterinary and human literature and surgical treatment can be confidently recommended.

In the last few years, OC lesions and articular cartilage injuries have been repaired using the osteochondral autograft transfer system (Cook et al., 2008; Arthrex, Inc.), in which a circular plug of healthy articular cartilage attached to subchondral bone is harvested from a non-articular site, such as the lateral trochlear ridge of the femur, and placed into a matching defect created at the site of the cartilage lesion (Cook et al., 2008; Fitzpatrick et al., 2009c). To date there is only one case series describing the use of the system in 33 elbows, 30 of which also had FCP (90.9%). The authors reported good short-term clinical results, but less encouraging results on arthroscopic follow up after 12–18 weeks (Fitzpatrick et al., 2009c). The study was complicated by the high prevalence of concurrent elbow pathology and frequent bilateral elbow disease.

There is no published confirmation that osteochondral autograft transfer is beneficial for dogs with articular cartilage lesions in the elbow, although there is some low level evidence for applications in the stifle. Treatment of human articular cartilage defects with OATS is well established, but the procedure cannot be recommended in canine elbows until randomised clinical trials are undertaken, particularly in light of the potential morbidity associated with harvest from the donor joint.

Medial coronoid disease

Diagnosis of medial coronoid disease by radiography is difficult, as the coronoid process cannot be imaged without overlying bony structures (Cook and Cook, 2009). CT has a published sensitivity of 71–88% and an approximate specificity of 85% for fragment detection when compared to arthroscopy or arthrotomy, respectively. However, a recent report found that CT and arthroscopy identified different types of lesions, suggesting that the modalities are complementary and ideally should be combined (Carpenter et al., 1993; Moores et al., 2008).

A number of studies have attempted to define the optimum treatment for various manifestations of medial coronoid disease, including fragment removal via arthrotomy or arthroscopy (Burton et al., 2010; Evans et al., 2008; Palmer, 2010), subtotal coronoidectomy (Fitzpatrick, 2006), cartilage debridement (Palmer, 2010), proximal ulna osteotomy (Preston et al., 2001; Turner et al., 1998), biceps/brachialis muscle release (Fitzpatrick and Yeadon, 2009) and medical management (Burton et al., 2010; Evans et al., 2008). From an EBM perspective, the literature is weak, consisting primarily of expert opinion, case series with low case numbers, variable outcome parameters, inconsistent diagnostic criteria and short follow-up times. To the authors' knowledge, there are only two prospective trials with low case numbers (Burton et al., 2010), which limits effective discrimination between treatment

alternatives. Therefore, treatment recommendations should be interpreted in light of these limitations.

There have been several studies comparing the outcomes of the arthrotomy, arthroscopy and medical management. Arthroscopic fragment removal resulted in reduced morbidity and better outcomes than arthrotomy or conservative management when disease was not advanced (Bouck et al., 1995; Evans et al., 2008; Meyer-Lindenberg et al., 2003; Palmer, 2010). However, no difference between treatment groups could be identified in a prospective treatment trial with low case numbers which compared arthroscopic treatment with conservative treatment (Burton et al., 2010).

Subtotal coronoidectomy (SCO) has been advocated because of the inconsistent results seen with fragment removal alone, and because of evidence of wide spread medial coronoid pathology (Danielson et al., 2006; Fitzpatrick et al., 2009a). It was hypothesised that subchondral bone sclerosis and the presence of micro-fissures would be associated with continuing joint pain and inflammation (Palmer, 2010). Subtotal coronoidectomy has been suggested to treat moderate to severe cartilage lesions on either the medial coronoid or humerus and fragmentation at the radial incisure (Fitzpatrick, 2011). No studies have been performed comparing SCO to fragment retrieval alone and one small study reported accelerated cartilage loss following SCO (Böttcher, 2011a). Currently the use of SCO can be cautiously justified in the presence of widespread medial coronoid pathology, but further research is required to define indications and outcomes of SCO and to validate the usefulness of the procedure in a clinical setting.

Cartilage injury of varying severity is commonly identified in medial coronoid disease (Punke et al., 2009; Samoy et al., 2012). Typically, cartilage damage is seen on the medial coronoid process or the contact area opposite, on the humerus (Punke et al., 2009; Samoy et al., 2012). When cartilage disease is mild (Outerbridge score I to III), conservative treatment is justified and other joint pathology should be treated as required. If the cartilage injury is severe (Outerbridge IV to V), a more aggressive approach might be indicated, such as SCO, PUO, or a palliative procedure (Table 1) (Fitzpatrick and Yeadon, 2009). Lesions in the humeral condyle are best treated by curettage of the damaged cartilage followed by burring to the level of bleeding subchondral bone, or drilling/micropicking to encourage infill of the lesion with new fibrocartilage (Breur and Lambrechts, 2012; Sams, 2000). The use of osteochondral autograft transfer, also called OATS, could also be a potential treatment option, but further work is required to establish indications and potential benefits.

United anconeal process

Ununited anconeal process has been treated with three different procedures, namely (1) proximal ulnar osteotomy; (2) anconeal process removal, and (3) anconeal process reattachment (Fox et al., 1996; Meyer-Lindenberg et al., 2001; Roy et al., 1994; Sjöström et al., 1995; Turner et al., 1998). Medical management has been shown to be inferior to surgical intervention and is associated with

Table 1
Modified Outerbridge scoring system.

Score	Description of cartilage appearance
0	Normal
1	Softening of the cartilage assessed with a probe (Outerbridge)
2	Partial thickness fibrillation
3	Deep fibrillation
4	Full thickness cartilage loss
5	Eburnated subchondral bone

Scoring system used for arthroscopic evaluation of cartilage injury (Fitzpatrick et al., 2009c).

Table 2
Evidence based medicine levels of evidence.^a

Level	Evidence quality
1a	Systematic review of randomized controlled trials
1b	Individual randomized control trial
2a	Systematic review of cohort studies
2b	Individual cohort study or low quality randomized controlled trial
2c	Outcomes research
3a	Systematic review of case-control studies
3b	Individual case-control study
4	Case-series and lower quality cohort and case-control studies
5	Expert opinion without explicit critical appraisal, or based on physiology, bench research or first principles
<i>Grades of recommendation</i>	
A	Consistent level 1 studies
B	Consistent level 2 or 3 studies or extrapolations from level 1 studies
C	Level 4 studies or extrapolations from level 2 or 3 studies
D	Level 5 evidence or troublingly inconsistent or inconclusive studies of any level

^a The Oxford Centre of Evidence Based Medicine. <http://www.cebm.net/?o=1025> (Accessed 1 September 2012).

more rapid progression of osteoarthritis (Cross and Chambers, 1997). Unfortunately, the level of evidence on which to base clinical decision making for all of these procedures is low, consisting entirely of case series with low numbers and relatively short follow up.

Union of the anconeal process was not consistently achieved in any of the reports and superior clinical outcome was not demonstrated with any single procedure. However, based on the data available from two studies of UAP fixation and concurrent ulna osteotomy, this procedure can be tentatively recommended, based on documented excellent clinical results and minimal progression of osteoarthritis (Krotscheck et al., 2000; Meyer-Lindenberg et al., 2001). In order to definitively recommend one treatment over another, a larger randomised prospective trial is required.

Palliative procedures

Palliative procedures are undertaken when the joint disease is sufficiently severe that addressing the suspected underlying pathology and secondary sequelae is likely to be insufficient, or when more conservative treatment has failed. Procedures currently in this category are those that unload the medial joint compartment, replace joint surfaces, manage pain or remove the source of pain (Baeumlin et al., 2010).

Unloading the medial joint compartment has been performed over the last few years by two methods: (1) the sliding humeral osteotomy (SHO; Hazewinkel et al., 1995) and (2) the proximal abducting ulnar osteotomy (PAUL). The SHO transfers weight from the medial joint compartment laterally in the joint and is performed by osteotomy of the mid humerus, with application of a stepped locking plate that translates the distal humerus medially (Fujita et al., 2003; Schulz et al., 2011). One case series of 59 elbows treated with SHO examined medium term outcomes (Fitzpatrick et al., 2009b) and reported generally good to excellent outcomes, with 21/32 elbows (65.6%) becoming sound and 10/32 elbows (31.3%) being grade 1/5 lame by 26 weeks post-operatively. High complication rates were also reported and further studies with larger case numbers, longer follow up times and data from other clinical groups are required before this procedure can be recommended, particularly as the long-term fate of replacement fibrocartilage is unknown in the dog.

Other procedures under development include PAUL, designed to unload the medial joint compartment and the canine unicompartmental elbow procedure, which implants artificial load-bearing surfaces into the humerus and ulna. There is little or no clinical

published data available regarding the effectiveness of these procedures.

Total elbow arthroplasty has been in use for over 10 years, but is not commonly used in the management of end-stage elbow dysplasia because of perceived surgical complexity, high complication rates and variable post-operative outcomes (Acker and Van Der Meulen, 2008; Conzemius et al., 2001; Conzenius, 2009). It can be recommended only in end stage disease and dog owners should be warned about the high rate of complications and variable outcomes potentially associated with the procedure.

Arthrodesis of the elbow has been performed to relieve the pain associated with chronic elbow osteoarthritis but the procedure results in substantial functional lameness. Arthrodesis is associated with significant residual disability and can only be recommended as a treatment of last resort (Fitzpatrick and Yeadon, 2009).

Elbow denervation has recently been described in a cadaveric study followed by testing in four healthy dogs to assess the effect of the procedure on limb function and to ascertain whether it was repeatable (Zamprogno et al., 2011). The study found that the sensory nerves to the elbow could be reliably identified and transected without compromise to cutaneous sensation or limb function. The study did not ascertain the effect of denervation on dogs with osteoarthritis. Until clinically research is completed, the procedure cannot be recommended.

Conclusions

Joint incongruity is now recognised as the major cause for the various manifestations of elbow dysplasia, although OC also seems to play a role in some canine patients. Joint incongruity is likely to occur because of radioulnar length mismatch, in which the radial head articulates above or below the medial coronoid process and so transmits excessive force to either the medial coronoid process or the anconeal process, but the exact mechanism is likely to be more complex and is still not understood. Other forms of incongruity have been suggested, but are currently not well supported in the literature.

Treatment should be aimed at correcting any pathology within the joint (when possible) and could include the retrieval of loose fragments, the resection of damaged subchondral bone and debridement or replacement of damaged cartilage. Ideally, procedures should be performed arthroscopically. If the elbow is seriously compromised, palliative procedures are available, but most need further study to determine their efficacy and appropriate indications. It is important to note that the lack of objective measures such as gait analysis and the potential confounding effects of other supportive therapies reduce the value of what is published regarding the treatment of elbow dysplasia in dogs. In particular, biomechanical testing of the elbow joint to improve our understanding of canine gait is important research which could establish appropriate treatment alternatives for this common and debilitating disease.

Conflict of interest statement

The author of this paper has no financial or personal relationship with other people or organisations that could inappropriately influence or bias the content of the paper.

References

- Acker, R., Van Der Meulen, G.T., 2008. Total elbow arthroplasty. Presented at 35th Veterinary Orthopedic Society (VOS) Annual Conference, Big Sky, MT, 8–15 March 2008.
- Baeumlin, Y., De Rycke, L., Van Caelenberg, A., Van Bree, H., Gielen, I., 2010. Magnetic resonance imaging of the canine elbow: An anatomic study. *Veterinary Surgery* 39, 566–573.

- Bennett, D., Duff, S.R.I., Kene, R.O., et al., 1981. Osteochondritis dissecans and fragmentation of the coronoid process in the elbow joint of the dog. *Veterinary Record* 109, 329–336.
- Blond, L., Dupuis, J., Beauregard, G., Breton, L., Moreau, M., 2005. Sensitivity and specificity of radiographic detection of canine elbow incongruence in an in vitro model. *Veterinary Radiology and Ultrasound* 46, 210–216.
- Böttcher, P., 2011a. Accelerated cartilage loss following subtotal coronoid ostectomy. In: *Proceedings of the American College of Veterinary Surgeons Symposium*, Chicago, USA, pp. 108–109.
- Böttcher, P., 2011b. Radio-ulnar incongruence in dogs with elbow dysplasia. In: *Proceedings of the American College of Veterinary Surgeons Symposium*, Chicago, USA, pp. 110–112.
- Bottcher, E., Werner, H., Ludewig, E., Grevel, V., Oechtering, G., 2009. Visual Estimation of radioulnar incongruence in dogs using three-dimensional image rendering: An in vitro study based on computed tomographic imaging. *Veterinary Surgery* 38, 161–168.
- Bouck, G.R., Miller, C.W., Taves, C.L., 1995. A comparison of surgical and medical treatment of fragmented coronoid process and osteochondritis dissecans of the canine elbow. *Veterinary and Comparative Orthopedics and Traumatology* 8, 177–183.
- Breuer, G.J., Lambrechts, N.E., 2012. Osteochondrosis. In: Tobias, K.M., Johnson, S.A. (Eds.), *Veterinary Surgery Small Animal*. Elsevier Saunders, St. Louis, MO, USA, pp. 1179–1189.
- Burton, N.J., Owen, M.R., 2008. Canine elbow dysplasia 2. Treatment and prognosis. *In Practice* 30, 552–557.
- Burton, N.J., Toscano, M.J., Barr, F.J., Owen, M.R., 2008. Reliability of radiological assessment of ulnar trochlear notch sclerosis in dysplastic canine elbows. *Journal of Small Animal Practice* 49, 572–576.
- Burton, N.J., Owen, M.R., Kirk, L.S., Toscano, M.J., Colborne, G.R., 2010. Conservative versus arthroscopic management for medial coronoid process disease in dogs: A prospective gait evaluation. In: *The British Veterinary Orthopaedic Association Meeting*, Austin Court, Birmingham, UK, pp. 792–780.
- Carpenter, L.G., Schwarz, P.D., Lowry, J.E., Park, R.D., Steyn, P.F., 1993. Comparison of radiologic imaging techniques for diagnosis of fragmented medial coronoid process of the cubital joint in dogs. *Journal of the American Veterinary Medical Association* 203, 78–83.
- Clements, D.N., 2006. Gene expression in normal and diseased elbows. In: *Proceedings of the Autumn Meeting of the British Veterinary Orthopaedic Association*, Chester, UK, pp. 6–7.
- Collins, K.E., Cross, A.R., Lewis, D.D., Zapata, J.L., Goett, S.D., Newell, S.M., Rapoff, A.J., 2001. Comparison of radius of curvature of the ulnar trochlear notch of Rottweilers and Greyhounds. *American Journal of Veterinary Research* 62, 968–973.
- Conzemius, M.G., Aper, R.L., Hill, C.M., 2001. Evaluation of a canine total-elbow arthroplasty system: A preliminary study in normal dogs. *Veterinary Surgery* 30, 11–20.
- Conzenius, M., 2009. Nonconstrained elbow replacement in dogs. *Veterinary Surgery* 38, 279–284.
- Cook, C.R., Cook, J.L., 2009. Diagnostic imaging of canine elbow dysplasia: A review. *Veterinary Surgery* 38, 144–153.
- Cook, J.L., Hudson, C.C., Kuroki, K., 2008. Autogenous osteochondral grafting for treatment of stifle osteochondrosis in dogs. *Veterinary Surgery* 37, 311–321.
- Cross, A.R., Chambers, J.N., 1997. Ununited anconeal process of the canine elbow. *Compendium on Continuing Education for the Practicing Veterinarian* 19, 349–361.
- Danielson, K.C., Fitzpatrick, N., Muir, P., Manley, P.A., 2006. Histomorphometry of fragmented medial coronoid process in dogs: A comparison of affected and normal coronoid processes. *Veterinary Surgery* 35, 501–509.
- Eckman, S., Carlson, C., 1998. The pathophysiology of osteochondrosis. *Veterinary Clinics of North America; Small Animal Practice* 28, 17–32.
- Evans, R.B., Gordon-Evans, W.J., Conzemius, M.G., 2008. Comparison of three methods for the management of fragmented medial coronoid process in the dog. A systematic review and meta-analysis. *Veterinary and Comparative Orthopedics and Traumatology* 21, 106–109.
- Fitzpatrick, N., 2006. Subtotal coronoid ostectomy (SCO) for the treatment of medial coronoid disease: A prospective study of 228 dogs (389 elbows) evaluating short and medium term outcome. In: *Proceedings British Veterinary Orthopaedic Association, Autumn Scientific Meeting—Enigmas of the Canine Elbow*, Chester, UK, pp. 22–29.
- Fitzpatrick, N., 2009. Biceps ulnar release procedure for treatment of medial coronoid disease in 49 elbows. In: *Proceedings of 36th Annual Conference, Veterinary Orthopaedic Society, Steamboat Springs, Colorado, USA*, p. 44.
- Fitzpatrick, N., 2011. Subtotal coronoid ostectomy: Indications and outcome. In: *Proceedings of the American College of Veterinary Surgeons Symposium*, Chicago, USA, pp. 113–118.
- Fitzpatrick, N., Yeadon, R., 2009. Working algorithm for treatment decision making for developmental disease of the medial compartment of the elbow in dogs. *Veterinary Surgery* 38, 285–300.
- Fitzpatrick, N., Smtih, T.J., Evans, R.B., Yeadon, R., 2009a. Radiographic and arthroscopic findings in the elbow joints of 263 dogs with medial coronoid disease. *Veterinary Surgery* 38, 213–233.
- Fitzpatrick, N., Yeadon, R., Smtih, T.J., Schulz, K., 2009b. Techniques of application and initial clinical experience with sliding humeral osteotomy for treatment of medial compartment disease of the canine elbow. *Veterinary Surgery* 38, 261–278.
- Fitzpatrick, N., Yeadon, R., Smtih, T.J., 2009c. Early clinical experience with osteochondral autograft transfer for treatment of osteochondritis dissecans of the medial humeral condyl in dogs. *Veterinary Surgery* 38, 246–260.
- Fox, D.J., 2012. Radius and ulna. In: Tobias, K.M., Johnson, S.A. (Eds.), *Veterinary Surgery Small Animal*. Elsevier Saunders, St. Louis, MO, USA, pp. 761–784.
- Fox, S.M., Burbidge, H.M., Bray, J.C., Guerin, S.R., 1996. Ununited anconeal process: Lag-screw fixation. *Journal of the American Animal Hospital Association* 32, 52–56.
- Fujita, Y., Schultz, K.S., Mason, D.R., Kaas, P.H., Stover, S.M., 2003. Effect of humeral osteotomy on joint surface contact in canine elbow joints. *American Journal of Veterinary Research* 64, 506–511.
- Gemmill, T.J., Mellor, D.J., Clements, D.N., Clarke, S.P., Farrell, M., Bennett, D., Carmichael, S., 2005. Evaluation of elbow incongruency using reconstructed CT in dogs suffering fragmented coronoid process. *Journal of Small Animal Practice* 46, 327–333.
- Grandalen, J., Lingsaas, F., 1991. Arthrosis in the elbow joint of young rapidly growing dogs: A genetic investigation. *Journal of Small Animal Practice* 32, 460–464.
- Grondalen, J., Grondalen, T., 1981. Arthrosis in the elbow joint of young rapidly growing dogs. V. A pathoanatomical investigation. *Nordisk Veterinaermedicin* 33, 1–16.
- Hazewinkel, H.A.W., 2006. Clinical investigation and aetiology of elbow dysplasias. In: *Proceedings of the 21st Annual Meeting of the International Elbow Working Group*, Prague, Czech Republic, pp. 5–11.
- Hazewinkel, H.A.W., Meij, B.P., Nap, R.C., Dijkshoorn, N.E., Ubbink, G., Wolvinkamp, W., 1995. Radiographic views for elbow dysplasia screening in Bernese Mountain Dogs. In: *Proceedings of the 7th International Elbow Working Group Meeting*, Constance, Germany, pp. 29–32.
- House, M.R., Marino, D.J., Lesser, M.L., 2009. Effect of limb position on elbow congruity with CT evaluation. *Veterinary Surgery* 38, 154–160.
- Hulse, D., 2008. Co-contraction of the biceps/brachialis muscle complex produces a rotational moment which may induce fragmentation/microfracture of the medial coronoid. In: *Proceedings of the American College of Veterinary Surgeons Symposium*, San Diego, USA, p. 466.
- Hulse, D., Young, B., Beale, B., 2010. Relationship of the biceps–brachialis complex to the medial coronoid process of the canine ulna. *Veterinary and Comparative Orthopedics and Traumatology* 23, 172–176.
- Kirberger, R.M., Fourie, S.L., 1998. Elbow dysplasia in the dog: Pathophysiology, diagnosis and control. *Journal of the South African Veterinary Association* 69, 43–54.
- Kramer, A., Holsworthy, I.G., Wisner, E.R., Kass, P.H., Schultz, K.S., 2006. Computed tomographic evaluation of canine radioulnar incongruence in vivo. *Veterinary Surgery* 35, 24–29.
- Krotscheck, U., Hulse, D.A., Bahr, A., Jerram, R.M., 2000. Ununited anconeal process: Lag-screw fixation with proximal ulnar osteotomy. *Veterinary and Comparative Orthopedics and Traumatology* 13, 212–216.
- Lewis, T.W., Iliska, J.J., Blott, S.C., Woolliams, J.A., 2011. Genetic evaluation of elbow scores and the relationship with hip scores in UK Labrador retrievers. *The Veterinary Journal* 189, 227–233.
- Ma, K., Janss, L.L.G., Groen, A.F., Liinama, A.E., Ojala, M., 2004. An indication of major genes affecting hip and elbow dysplasia in four Finnish dog populations. *Heredity* 92, 402–408.
- Mason, D.R., Schulz, K.S., Samii, V.F., Fujita, J., Hornof, V.J., Herrgesell, V.J., Long, D.D., Morgan, J.P., Kass, P.H., 2002. Sensitivity of radiographic evaluation of radioulnar incongruence in the dog in vitro. *Veterinary Surgery* 31, 125–132.
- Meyer-Lindberg, A., Fehr, M., Nolte, I., 2006. Co-existence of UAP and FCP of the ulna in the dog. *Journal of Small Animal Practice* 47, 61–65.
- Meyer-Lindberg, A., Fehr, M., Nolte, I., 2001. Short- and long-term results after surgical treatment of an ununited anconeal process in the dog. *Veterinary and Comparative Orthopedics and Traumatology* 14, 101–110.
- Meyer-Lindberg, A., Langhann, A., Fehr, M., Nolte, I., 2003. Arthrotomy versus arthroscopy in the treatment of the fragmented medial coronoid process of the ulna (FCP) in 421 dogs. *Veterinary and Comparative Orthopedics and Traumatology* 16, 204–210.
- Moores, A.P., Benigni, L., Lamb, C.R., 2008. Computed tomography versus arthroscopy for the detection of canine elbow dysplasia lesions. *Veterinary Surgery* 37, 390–398.
- Morgan, J., Wind, A., Davidson, A., 1999. Bone dysplasias in the labrador retriever: A radiographic study. *Journal of the American Animal Hospital Association* 35, 332–340.
- Morgan, J., Wind, A., Davidson, A.P., 2000. Elbow Dysplasia. *Hereditary Bone and Joint Diseases in the Dog*, First Ed. Hannover Schultersche, Germany, p. 41.
- Nap, R.C., 1995. Pathophysiology and clinical aspects of canine elbow dysplasia. In: *Proceedings of the 7th International Elbow Working Group Meeting*, Constance, Germany, pp. 6–8.
- Narojek, T., Fiszdoni, K., Hanysz, E., 2008. Canine elbow dysplasia in different breeds. *The Bulletin of the Veterinary Institute in Pulawy* 52, 169–173.
- Olsson, S.E., 1983. The early diagnosis of fragmented coronoid process and osteochondritis dissecans of the canine elbow joint. *Journal of the American Animal Hospital Association* 19, 616–626.
- Olsson, S.E., 1993. Pathophysiology, morphology, and clinical signs of osteochondrosis in the dog. In: *Disease Mechanisms in Small Animal Surgery*, Second Ed. Lea and Febiger, Philadelphia, USA, pp. 777–796.
- Outerbridge, R.E., 1961. The etiology of chondromalacia patellae. *Journal of Bone and Joint Surgery* 43, 753–757.

- Padgett, G.A., Mostosky, U.V., Probst, C.W., Thomas, M.W., Krecke, C.F., 2005. The inheritance of osteochondritis dissecans and fragmented medial coronoid process of the elbow joint in Labrador retrievers. *Journal of the American Animal Hospital Association* 31, 327–330.
- Palmer, R.H., 2010. Arthroscopic and open surgical treatment of MCPD/OCD. In: *Proceedings 25th annual meeting of the International Elbow Working Group, Bologna, Italy*, pp. 14–20.
- Palmer, R.H., 2011. BURP: Arthroscopy vs. mini-arthrotomy. In: *Proceedings of the American College of Veterinary Surgeons Symposium, Chicago, USA*, pp. 120–122.
- Preston, C.A., Schulz, K.S., Kass, P.H., 2000. In vitro determination for contact areas in the normal elbow joint of dogs. *American Journal of Veterinary Research* 61, 1315–1321.
- Preston, C.A., Schulz, K.S., Taylor, K.T., Kass, P.H., Hagan, C.E., Stover, S.M., 2001. In vitro experimental study of the effect of radial shortening and ulnar osteotomy on contact patterns in the elbow joint of dogs. *American Journal of Veterinary Research* 62, 1548–1556.
- Proks, P., Necas, A., Stehlik, L., Srnc, R., Griffon, D.J., 2011. Quantification of humeroulnar incongruity in Labrador retrievers with and without medial coronoid disease. *Veterinary Surgery* 40, 981–986.
- Punke, J.P., Hulse, D.A., Kerwin, S.C., Peycke, L.E., Budsberg, S.C., 2009. Arthroscopic documentation of elbow cartilage pathology in dogs with clinical lameness without changes on standard radiographic projections. *Veterinary Surgery* 38, 209–212.
- Roy, R.G., Wallace, L.J., Johnston, G.R., 1994. A retrospective long-term evaluation of ununited anconeal excision on the canine elbow. *Veterinary and Comparative Orthopedics and Traumatology* 7, 94–97.
- Samoy, Y., Van Ryssen, B., Gielen, I., Walschot, N., van Bree, H., 2006. Review of the literature: Elbow incongruity in the dog. *Veterinary and Comparative Orthopedics and Traumatology* 19, 1–8.
- Samoy, Y., Van Vynckt, D., Gielen, I., van Bree, H., Duchateau, L., Van Ryssen, B., 2012. Arthroscopic findings in 32 joints affected by severe elbow incongruity with concomitant fragmented medial coronoid process. *Veterinary Surgery* 41, 355–361.
- Sams, A.E., 2000. Canine elbow joint arthroscopy: Introduction and description of technique. *Compendium on Continuing Education for the Practicing Veterinarian* 22.
- Schulz, K.S., Fitzpatrick, N., Young, R., 2011. Theory and development of the sliding humeral osteotomy. In: *Proceedings of the American College of Veterinary Surgeons Symposium, Chicago, USA*, pp. 263–265.
- Sjostrom, L., 1998. Ununited anconeal process in the dog. *Veterinary Clinics of North America; Small Animal Practice* 28, 75–86.
- Sjöström, L., Kasstöm, H., Källber, M., 1995. Ununited anconeal process in the dog. Pathogenesis and treatment by osteotomy of the ulna. *Veterinary and Comparative Orthopedics and Traumatology* 8, 170–176.
- Tromblee, T.C., Jones, J.C., Bahr, A.M., Shires, P.K., Aref, S., 2007. Effect of computed tomography display window and image plane on diagnostic certainty for characteristics of dysplastic elbow joints in dogs. *American Journal of Veterinary Research* 68, 858–871.
- Trostel, C.T., McLaughlin, R.M., Pool, R.R., 2003. Canine lameness caused by developmental orthopedic diseases: Fragmented medial coronoid process and ununited anconeal process. *Compendium on Continuing Education for the Practicing Veterinarian* 25, 112–120.
- Turner, B.M., Abercromby, R.H., Innes, J., McKee, W.M., Ness, M.G., 1998. Dynamic proximal ulnar osteotomy for the treatment of ununited anconeal process in 17 dogs. *Veterinary and Comparative Orthopedics and Traumatology* 11, 76–79.
- Van Ryssen, B., Van Bree, H., 1998. Arthroscopic findings in 100 dogs with elbow lameness. *Veterinary Record* 140, 360–362.
- Van Sickle, D.C., 1966. A comparative study of the postnatal elbow development of the Greyhound and the German Shepherd dog. *Journal of the American Veterinary Medical Association* 147, 1650–1651.
- Vermote, K.A.G., Bergenhuysen, A.L.R., Gielen, I., van Bree, H., Duchateau, L., Van Ryssen, B., 2010. Elbow lameness in dogs of six years and older. Arthroscopic and imaging findings of medial coronoid disease in 51 dogs. *Veterinary and Comparative Orthopedics and Traumatology* 23, 43–50.
- Williams, S.B., Wilson, A.M., Daynes, J., Peckham, K., Payne, R.C., 2008. Functional anatomy and muscle moment arms of the thoracic limb of an elite sprinting athlete: The racing greyhound (*Canis familiaris*). *Journal of Anatomy* 213, 373–382.
- Wind, A., 1986a. Elbow incongruity and developmental elbow disease in the dog: Part I. *Journal of the American Animal Hospital Association* 22, 711–724.
- Wind, A., 1986b. Elbow incongruity and developmental elbow disease in the dog: Part II. *Journal of the American Animal Hospital Association* 22, 725–730.
- Wolschrijn, C.F., Gruys, E., Weijs, W.A., 2005. Microcomputed tomography and histology of a fragmented medial coronoid process in a 20-week-old golden retriever. *Veterinary Record* 157, 383–386.
- Ytrehus, B., Carlson, C.S., Ekman, S., 2007. Etiology and pathogenesis of osteochondrosis. *Veterinary Pathology* 44, 229–248.
- Zamprogn, H., Hash, J., Hulse, D.A., Lascelles, D.X., 2011. Elbow denervation in dogs: Development of an in vivo surgical procedure and pilot testing. *The Veterinary Journal* 190, 220–224.